

Isolated Retinal Capillary Hemangioblastoma: A Rare Case

by Habibah Muhiddin

Submission date: 18-Jun-2021 10:32AM (UTC+0700)

Submission ID: 1608359310

File name: 021_Isolated_Retinal_Capillary_Hemangioblastoma_A_rare_case.pdf (742.86K)

Word count: 2403

Character count: 13030

5 Isolated Retinal Capillary Hemangioblastoma: A Rare Case

Viviyanti, Habibah S. Muhiddin, Budu, Andi Muh. Ichsan,
A. Suryanita Tajuddin, Idayani Panggalo, Dyah A. Windy

Department of Ophthalmology, Faculty of Medicine, Hasanuddin University,
Hasanuddin University Teaching Hospital, Makassar, Indonesia

ABSTRACT

4
Retinal Capillary Hemangioblastoma (RCH) generally has clinical onset in first two decades of life. It is associated with Von Hippel Lindau (VHL) disease because RCH is the most frequent and earliest manifestation of VHL disease. A 20 years-old-male presented with painless blurred vision in left eye since 2 weeks prior to the admission and no other complaint. He had no significant medical history, trauma and family history. His best corrected visual acuity was 20/20 in right eye and 20/400 in left eye with normal anterior segment. Fundus examination on left eye revealed a globular reddish lesion with dilated feeding vessel and tortuous draining vein at the inferotemporal retina. The B-Scan Ultrasonography showed dome shaped lesion. We performed abdominal ultrasonography and brain MRI to detect other lesion but showed the normal results. Argon laser photocoagulation has performed as a treatment. Retinal Capillary Hemangioblastoma is one type of Retinal Hemangioma. The pathogenesis may associated with Von Hippel Lindau Disease by "VHL tumor suppressor gene" which is located on chromosome 3p25-26. The radiological imaging has performed to detect systemic lesion and showed the normal results. After argon laser photocoagulation treatment, the visual acuity became 20/300 and fundus examination showed the scar in margin tumor with shrinkage feeding vessel. Based on ophthalmology and systemic examinations, we found a Retinal Capillary Hemangioblastoma as the hallmark manifestation in this case. Early diagnosis and argon laser treatment has benefit in controlling progression of disease. Systemic long term follow-up still needed to detect multisystem predisposing lesion.

Keywords: *Retinal Capillary Hemangioma; Von Hippel Lindau; Argon Laser.*

INTRODUCTION

Based on clinical and histological characteristics, there are 2 types of retinal hemangiomas. There are cavernous hemangioma and capillary hemangioblastoma. Capillary hemangioblastoma is composed of tortuous, large-diameter capillaries lined by normal endothelium separated by polygonal interstitial stromal cells and usually have a "light bulb" appearance (Maher et al., 1990).

4
The Retinal Capillary Hemangioblastoma (RCH) or also known as retinal angioma is a vascular hamartoma that generally has clinical onset in the first second decades of life. The tumor is composed of a proliferation of endothelial and stromal glial cells. Immuno histochemical and immune cytochemical experiments have suggested that stromal cells are astrocytic, vasoformative stem cells and neuroectodermal in origin (Webster et al., 1999; Shanmugam & Ramanjulu, 2015). The Retinal

Capillary Hemangioblastoma may associated with Von Hippel Lindau (VHL) Disease because about 85%, RCH is the most frequent and earliest manifestation of the VHL disease. Von Hippel Lindau Disease is a rare, familial disorder involving multiple organs; retina, central nervous system, kidney, liver, etc. The VHL Disease is an autosomal dominant disorder with high penetrance and variable expressions, and occurs due to germline mutations of the VHL tumor suppressor gene located on the distal part of the short arm of the third chromosome (3p25-26). The incidence of isolated Retinal Capillary Hemangioblastoma is unknown, but any report the birth incidence of RCH is approximately 1 in 38.000. The tumor is usually detected by the second decade of life (Webster et al., 1999; Kim et al., 2014).

CASE PRESENTATION

A male 20 years old admitted to the hospital in January 2020, with blurred vision in his left eye. He realize when he did the eye test in the police department about 2 weeks prior to admission. No other complaint, such as pain, red eye, lacrimation or headache. No history of trauma, glasses, and ophthalmic surgery. No other systemic disease and family history.

General condition is normal, with blood pressure 120/70 mmHg, heart rate 76x/minute, and normal body temperature. Visual acuity for right eye 20/20 and best corrective visual acuity for the left eye was 20/400 with normal intraocular pressure for both eyes. Normal anterior segment was found with no specific sign in both eyes.



Figure 1. Anterior segment of the patient was normal for right (a) and left eye (b)

Normal funduscopy was found for the right eye (Figure.2) and for the left eye, we found a big size of Retinal Capillary Hemangioma (RCH) at the peripheral retina. The diameter size of RCH was equal to 3.5 diameter size of the optic disc. The RCH gives some characteristic, there are orange-red coloured, well defined circumscribed margin, and balloon like shaped mass with a dilated feeding vessels and tortuous draining vein (figure 3).

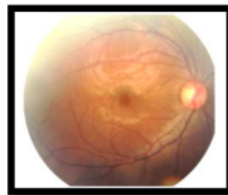


Figure 2. Normal Fundus Photography for Right Eye

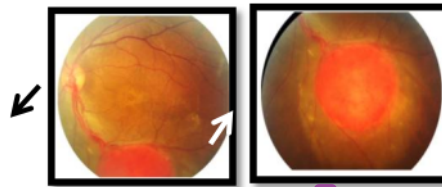


Figure 3. Fundus photography of the Left Eye, showed a dilated feeding Vessel and tortuous draining vein (black arrow) of the Tumor.

The Red-Orange and Round Shaped with well defined margin of Retinal Capillary Hemangioblastoma (white arrow).

The B-Scan Ultrasonography (USG) examination showed normal vitreous and a dome shaped appearance of the tumor in longitudinal section.

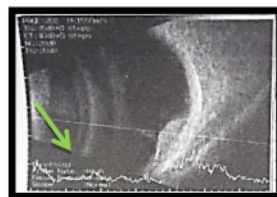

Figure 4. The USG Examination showed dome shaped appearance (green arrow).

Based on anamnesis and ophthalmic findings, we diagnosed the left eye of the patient as Retinal Capillary Hemangioma. Because RCH may associated with other lesion in brain and other visceral organs, such as liver, kidney, and spleen, we decided to do further radiological examination using abdominal ultrasonography (USG) and brain magnetic resonance imaging (MRI). The results were normal with no tumor found in brain (figure 6) and other visceral organs (figure 5).

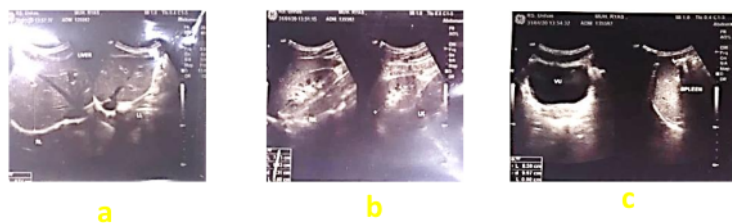


Figure 5. Abdomen Ultrasonography showed normal structure of the Liver (a), Kidney (b), and Spleen (c). No tumor found in visceral organs.

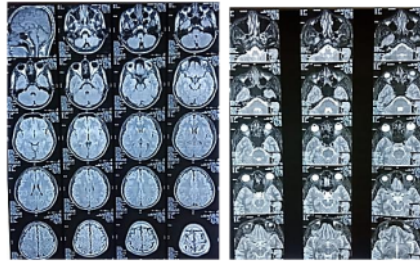


Figure 6. MRI of Brain showed no tumor found

Argon laser photocoagulation as a treatment had performed for this patient in February 2020. We performed laser photocoagulation around the lesion and at the dilated feeding vessel.

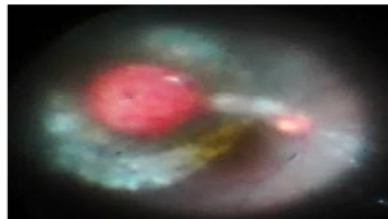


Figure 7. Treatment Laser Photocoagulation for Retinal Capillary Hemangioblastoma.

First day after laser treatment, the visual acuity for left eye remain 20/400 and the intra ocular pressure was normal.

Three weeks after treatment, the visual acuity in the left eye became 20/300. There was an improvement visual acuity but not significant. Fundus examination showed laser scarring at the feeding vessel and around the lesion.

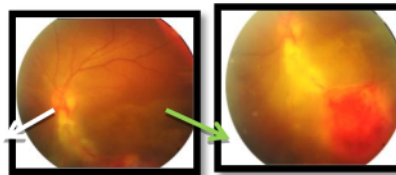


Figure 8. Fundus Photography of the Left Eye in 3 weeks after surgery with laser scarring at the feeding vessels (white arrow) and at around margin lesion (green arrow)

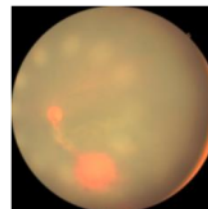


Figure 9. Retcam Imaging for the left eye in 3 weeks after surgery showed the laser scarring of the vessel and lesion.

The B Scan Ultrasonography (USG) control showed the normal vitreous and tumor appearance in axial section. But unfortunately, we could not compare the tumor thickness before and after surgery due to the different section used in B-Scan USG Examination.

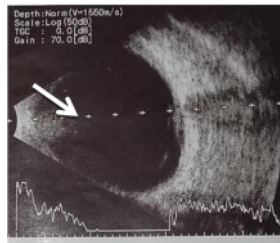


Figure 10. B Scan Ultrasonography 3 weeks after surgery in axial section. It showed normal vitreous and a tumor appearance (white arrow)

DISCUSSION

This case showed the clinical presentation of the Retinal Capillary Hemangioblastoma (CH), including subjective clinical symptom until objective sign which found by ophthalmic examinations. Our patient is 20 years old male with Retinal Capillary Hemangioblastoma (RCH). The RCH most present at second decade years of age. Recent publications indicate that the retinal hemangioma is usually manifest by age 20-30. It is probability developed the RCH increases progressively with age (Wang et al., 2018; Mittal et al., 2018).

This patient complaint about blurry vision in his left eye since 2 weeks before admission with best corrective visual acuity was 20/400. Vision loss in patients with RCH may be the result of macular edema. Other causes of vision loss include the growth of peripheral hemangiomas that lead to an exudative retinal detachment. Because these tumors have a fibrous component with angiogenesis, increased fibrosis can lead the occurs of tractional retinal detachments (Wang et al., 2018; Dollfus et al., 2002).

The specific sign found by fundus examination. We found a Retinal Capillary Hemangioblastoma (RCH) appearance at the peripheral retina which have some characteristics; round, well defined circumscribed, red-orange coloured, with dilated feeding vessels as tumor supplier.

The pathology of RCH may associated with the Von Hippel Lindau Disease. The VHL disease was described in Von Hippel's literature in 1911 and Lindau's literature in 1926. Von Hippel Lindau Disease is a rare, familial disorder involving multiple organs; retina, central nervous system, kidney, liver, etc. The VHL Disease an autosomal dominant disorder with high penetrance and variable expressions, and occurs due to germline mutations of the VHL tumor suppressor gene. Identification of the VHL disease gene was published in 1993. The responsible gene was named as 'VHL tumor suppressor gene', which is located on the distal part of the short arm of the third chromosome 3p25-26. The stromal cells of the retinal angioma have a complete loss of VHL gene and enhanced Vascular Endotelial Growth Factors (VEGF) gene expression. The product of VHL suppressor gene

is known to downregulate VEGF expression. With the absence of pVHL, VEGF is up-regulated, resulting in neo-vascularization on and around these retinal capillary hemangiomas (Mittal et al., 2018; Atik et al., 2017).

Because the Retinal Capillary Hemangioblastoma may associated with lesion in brain and other visceral organs, we decided to performe further examination to track other lesion using Abdominal USG and brain MRI. The results of the radiological imaging (abdominal USG and brain MRI) were normal with no tumor found. Based on the results, we finally diagnosed the patient as a Retinal Capillary Hemangioblastoma. However, routine follow up should be undergone every 3-6 months for retinal examination and about 1-2 years for other systemic lesion screening, to improve the prognosis and prevent the complication related to these tumor by early detection and immediate treatment (Dollfus et al., 2002; Shields et al., 2015).

There are some strategies management of the RCH, including observation if the lesion less than 5.00 mm; cryotherapy and argon laser photocoagulation for big lesion (more than 5.00 mm); and vitrectomy surgery if retinal detachment occurs. Because we found a big size lesion in this case, we decided to perform laser photocoagulation immediately. Argon laser photocoagulation had been given around the lesion and feeding vessels to cut the lane supply of the tumor and hopefully inhibit the tumor enlargement. Retinal Capillary Hemangioblastoma with small lesion may remain stable for several years, but any study reported to enlarge. If RCH doesn't get the early intervention and become the late stages, it may have several complications; retinal detachment, massive exudation, uveitis, glaucoma and also pthysis (Mittal et al., 2018; Shields et al., 2015).

After laser treatment, the visual acuity on the left eye became 20/300. There was no significant improvement of visual acuity before and after treatment. The fundus examination showed the scar around the lesion with no significant decrease of tumor size. There are some other studies reported although the patient had given threatment, about 25 % of cases still have permanent loss of visual acuity due to the development of RCH which increase progressively with age (Dollfus et al., 2002; Shields et al., 2015).

CONCLUSION

Based on results of several ophthalmic and systemic examinations, we found a Retinal Capillary Hemangioblastoma (RCH) as the only manifestation in this case. However, the next routine follow-up and ystemic workout should be considered to evaluate another manifestation. So, it may improve the prognosis and prevent the complication related to these tumor.

REFERENCES

1. Atik S.S, Solmaz A. E & Oztas Z (2017), The Importance of Retinal Hemangioma in Diagnosis. Case Report. 2017:47:180-183. doi:10.4274/tjo.90912
2. Chew, E. Y. (2005). Ocular manifestations of von Hippel–Lindau disease: clinical and genetic investigations. *Transactions of the American Ophthalmological Society*, 103, 495.
3. Dollfus, H., Massin, P., Taupin, P., Nemeth, C., Amara, S., Giraud, S., ... & Richard, S. (2002). Retinal hemangioblastoma in von Hippel-Lindau disease: a clinical and molecular study. *Investigative ophthalmology & visual science*, 43(9), 3067-3074.
4. Kim, H., Jeong, H. Y., Kwon, H. J., Lee, C. S., & Lee, S. C. (2014). Therapeutic outcomes of retinal hemangioblastomas. *Retina*, 34(12), 2479-2486.
5. Maher, E. R., Yates, J. R. W., Harries, R., Benjamin, C., Harris, R., Moore, A. T., & Ferguson-Smith, M. A. (1990). Clinical features and natural history of von Hippel-Lindau

- disease. *QJM: An International Journal of Medicine*, 77(2), 1151-1163.
6. Mittal S, Sukhani P, Mishra H & Agarwal S (2018). Vascular Tumor of The Retina: A Case Report. Availbale from: www.iosrjournals.org. doi:10.9790/0853-1706148489
 7. Shanmugam, P. M., & Ramanjulu, R. (2015). Vascular tumors of the choroid and retina. *Indian journal of ophthalmology*, 63(2), 133
 8. Shields, C. L., Douglass, A. L. E. X. Z. A. N. D. R. A., Higgins, T. I. M. O. T. H. Y., Samara, W. A., & Shields, J. A. (2015). Retinal hemangiomas: understanding clinical features, imaging, and therapies. *Retina Today*, 10, 61-67.
 9. Wang, H., Shepard, M. J., Zhang, C., Dong, L., Walker, D., Guedez, L., ... & Chan, C. C. (2018). Deletion of the von Hippel-Lindau gene in hemangioblasts causes hemangioblastoma-like lesions in murine retina. *Cancer research*, 78(5), 1266-1274.
 10. Webster, A. R., Maher, E. R., & Moore, A. T. (1999). Clinical characteristics of ocular angiomas in von Hippel-Lindau disease and correlation with germline mutation. *Archives of Ophthalmology*, 117(3), 371-378.

Isolated Retinal Capillary Hemangioblastoma: A Rare Case

ORIGINALITY REPORT

19%

SIMILARITY INDEX

12%

INTERNET SOURCES

16%

PUBLICATIONS

4%

STUDENT PAPERS

PRIMARY SOURCES

- 1** [Christiane Berger, Ardeshir Mahdavi. "Exploring Cross-Modal Influences on the Evaluation of Indoor-Environmental Conditions", Frontiers in Built Environment, 2021](#) 2%
Publication
- 2** [thejns.org](#) 1%
Internet Source
- 3** [Arun D. Singh. "Solitary retinal capillary hemangioma: Lack of genetic evidence for von Hippel-Lindau disease", Ophthalmic Genetics, 3/1/2002](#) 1%
Publication
- 4** [www.thieme-connect.de](#) 1%
Internet Source
- 5** [annalsofrscb.ro](#) 1%
Internet Source
- 6** [jjco.oxfordjournals.org](#) 1%
Internet Source

7	John B. Kerrison. "Neuro-ophthalmology of the phacomatoses", Current Opinion in Ophthalmology, 12/2000 Publication	1 %
8	Peter H. Win, Tara A. Young. "Optos Panoramic200A™ Fluorescein Angiography for Proliferative Diabetic Retinopathy with Asteroid Hyalosis", Seminars in Ophthalmology, 2009 Publication	1 %
9	iovs.arvojournals.org Internet Source	1 %
10	worldwidescience.org Internet Source	1 %
11	S. BOM. "Sudden bilateral visual loss in acute myeloid leukaemia", British Journal of Ophthalmology, 2000 Publication	1 %
12	CHI-CHAO CHAN, ATIF BEN DANIEL COLLINS, EMILY Y. CHEW. "MOLECULAR PATHOLOGY OF EYES WITH VON HIPPEL-LINDAU (VHL) DISEASE", Retina, 2007 Publication	1 %
13	Submitted to Queensland University of Technology Student Paper	1 %

14

Internet Source

1 %

15

eyecancer.com

Internet Source

1 %

16

Antonello, Anthony, and George W. Weinstein. "Successful Treatment of Bacillus alvei Endophthalmitis", American Journal of Ophthalmology, 1989.

Publication

<1 %

17

thejournalofheadacheandpain.springeropen.com

Internet Source

<1 %

18

A H Alsuhaibani. "Confocal microscopy of the cornea in nephropathic cystinosis", British Journal of Ophthalmology, 2005

Publication

<1 %

19

J B Jonas. "Repeated intravitreal injection of triamcinolone acetonide for diffuse diabetic macular oedema", British Journal of Ophthalmology, 1/1/2005

Publication

<1 %

20

Y A Akova. "Sildenafil-associated consecutive nonarteritic anterior ischaemic optic neuropathy, cilioretinal artery occlusion, and central retinal vein occlusion in a haemodialysis patient", Eye, 01/2007

Publication

<1 %

pubs.rsna.org

21

Internet Source

<1 %

22

www.tandfonline.com

Internet Source

<1 %

23

"From the 16th International Neuro-ophthalmology Society (INOS) Congress 2006", *Neuro-Ophthalmology*, 2009

Publication

<1 %

24

Paul Enoksson. "Vitamin B12 Deficiency Affecting the Optic Nerve", *Acta Medica Scandinavica*, 04/24/2009

Publication

<1 %

25

"Encyclopedia of Ophthalmology", Springer Science and Business Media LLC, 2018

Publication

<1 %

26

Lonser, R.R.. "von Hippel-Lindau disease", *The Lancet*, 20030614

Publication

<1 %

27

Stéphane Richard. "von Hippel-Lindau disease: recent advances and therapeutic perspectives", *Expert Review of Anticancer Therapy*, 2014

Publication

<1 %

Exclude bibliography On